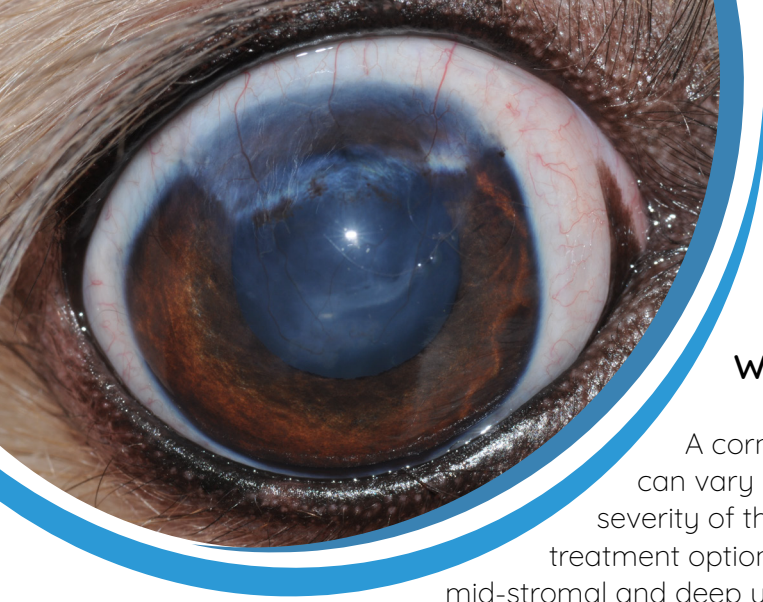


Corneal Surgery



What is a corneal ulcer?

A corneal ulcer is essentially a wound to the cornea. This wound can vary in depth, and it is this depth that we use to determine the severity of the ulcer. When thinking of severity of ulcers, and subsequent treatment options, we broadly classify ulcer into three categories: superficial, mid-stromal and deep ulcers.

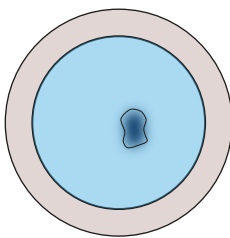
What surgical options are available to treat corneal ulcers?

All of the below procedures are carried out under the operating microscope. The ophthalmologists at EVC have been especially trained in microsurgical skills which allow handling of the tissue and suture material (which is barely thicker than a hair!) with minimal trauma.

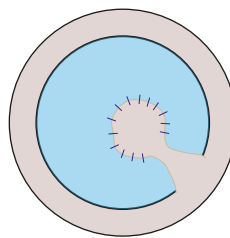
There are many different grafting procedures available, but the types of graft that we most commonly use here at EVC are the following:

1 Conjunctival pedicle graft (also called 'CPG')

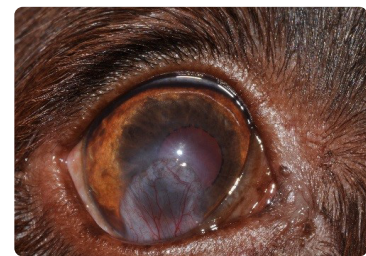In this grafting procedure, a thin piece of the conjunctiva (the pink skin that covers the white of the eye) is sown into the defect. The conjunctiva provides some structural support but also brings blood vessels into the ulcer, which in turn allow much faster healing of the wound than would usually be seen in the clear cornea. The conjunctival pedicle graft is especially suitable for superficial ulcers, small but deep corneal ulcers, and in cases of active corneal infection.



Eye with an ulcer



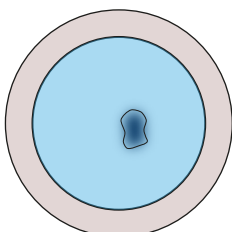
Eye with CPG over the ulcer



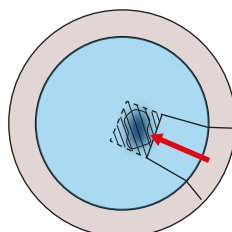
Eye with CPG over the ulcer

2 Corneo-conjunctival transposition graft (also called 'CCT')

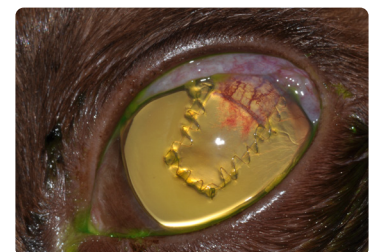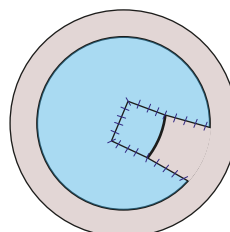
In this grafting procedure, a thin piece of healthy corneal tissue adjacent to the wound is taken with some attached conjunctiva, mobilised and sown into the defect. This graft is especially suitable for larger deep defects as it brings superior stability. In addition, this graft will give the best cosmetic and functional result as the piece of cornea sutured into the original defect will usually become clear again. This procedure may not be suitable in some cases of severe infectious corneal ulceration.



Eye with an ulcer



Eye with CCT over the ulcer



Eye with CCT over the ulcer

3 Foreign material graft (collagen or amnion)

These grafts are either harvested from other species such as pig gut or are bio-engineered (such as amnion). They are expensive but readily available to us and may help in cases where the corneal ulcer is so large that the above graft options (CPG and CCT) alone will not work.

What do I expect after my pet has undergone a corneal grafting procedure?

Most patients will require treatment with antibiotic eye drops or ointments for approximately 3 weeks post-operatively. As the graft heals into the surrounding tissue, a 'vascular' response may develop. This response may look scary to you, as the graft may become very red in appearance, but it welcomed by us as it means that the graft is becoming stable and secure. Once we know that the graft has fully integrated into the surrounding cornea, we will change your pet's medication to help clearing of this response.

When is the eye 'stable' after surgery – so that I can start to play and exercise normally with my pet?

Most grafts integrate and stabilise the operated eye within 14 days. During this time, we usually advise that the patient wears a protective collar and that exercise is limited to short lead walks for dogs, and that cats are kept indoors. If we feel that your pet's graft will take longer to 'safely' heal in, we will advise to limit exercise for longer.

Will my pet be able to see out of the operated eye after the operation?

Corneal grafting procedures are always carried out with the aim to maintain a sighted eye, and not for cosmetic reasons only. However, most grafting procedures will cause some scarring which can reduce vision and it will depend on the extent of the original wound as to how clear the cornea is in the end. On average, it will take between 3 and 6 months after the operation until the optimal post-operative result is achieved.

What can go wrong with a corneal grafting operation?

Corneal grafts are highly successful in the majority of cases. However, the condition of the eye before the procedure does have an impact on the chance of success of the operation. Eyes with very large defects or eyes where the ulcer has already ruptured, have a higher chance of failure.

Specific problems with grafting procedures include:

- Graft retraction – this means the graft pulls loose from the sutures and may no longer secure the defect

- Infection – loss of the graft or progression of ulceration despite the use of antibiotics

Complications with grafts can often be managed medically with additional treatment but may require additional surgery in some patients. The cost of such additional procedures is not included in the original quote for surgery and has to be discussed on a case-by-case basis as it is not possible to quote for every eventuality.

Finally, there are of course the risks that any general anaesthetic has to be considered. At EVC, we have state-of-the-art monitoring for your pet during anaesthetics and our team is extremely experienced – but general anaesthesia is never risk free.

In some cases, if the eye is not healing and we have exhausted all treatment options, we may recommend removal of the eye to make your pet comfortable. We will discuss your pet's progress with you every time we see you.



Eye Veterinary Clinic

VISION IS OUR MISSION

01568 616 616
www.eyevetclinic.co.uk
info@eyevetclinic.co.uk